



PRESENTING CLINICAL SIGNS

History: Grade 5/6 murmur. Previously diagnosed with degenerative valve disease. Asymptomatic.

DATE

No current medications.

7/15/22

ECHOCARDIOGRAPHIC FINDINGS

2D, M-mode, and Doppler study.

PERFORMED BY:

Kelly Vazquez

INTERPRETED BY

Keith Blass, DVM,
MS, DACVIM
(Cardiology)

There is moderate left atrial dilation. The mitral valve leaflets are thickened and exhibit systolic prolapse. A moderate jet of eccentric mitral regurgitation is present. There is moderate left ventricular dilation. Left ventricular systolic function is normal. The aorta and aortic valve appear normal, though trace aortic insufficiency is present. Right atrial and right ventricular dimensions are normal. The tricuspid valve leaflets are mildly thickened, and a mild jet of tricuspid regurgitation is present. TR velocity does not suggest the presence of pulmonary hypertension. The pulmonary artery and pulmonic valve are normal. No shunting lesions are visualized. No pericardial effusion or cardiac masses are seen.

PATIENT

Nuri Moon

LA - 39.3 mm
LVIDd - 39.8 mm
LVIDs - 23.0 mm
FS - 42%
RA - 24.8 mm
LVOT - 1.03 m/s
RVOT - 0.55 m/s
TR - 1.37 m/s

SPECIES

Canine

ASSESSMENT/RECOMMENDATIONS

Degenerative mitral and tricuspid valve disease

BREED

Mixed

This examination demonstrates progression of Nuri's mitral valve disease over the past year and a half, as she now has moderate secondary dilation of both her left atrium and left ventricle. While Nuri is still asymptomatic, the severity of her disease indicates that she is at risk for the development of clinical signs, such as coughing, exercise intolerance, syncope, and labored breathing, therefore, careful monitoring for these signs is recommended.

SEX

FS

Nuri's tricuspid valve disease is still mild and well-compensated.

AGE

9 y

I recommend starting Nuri on pimobendan (2.5 mg BID), as this medication should help to slow the progression of her mitral valve disease.

A recheck echocardiogram is recommended in 9 months. Thoracic radiographs are recommended if Nuri experiences respiratory clinical signs.

WEIGHT

22.8 lb

HOSPITAL NAME

Englewood Cliffs VH

REFERRING VET

Dr. Attansi



DATE

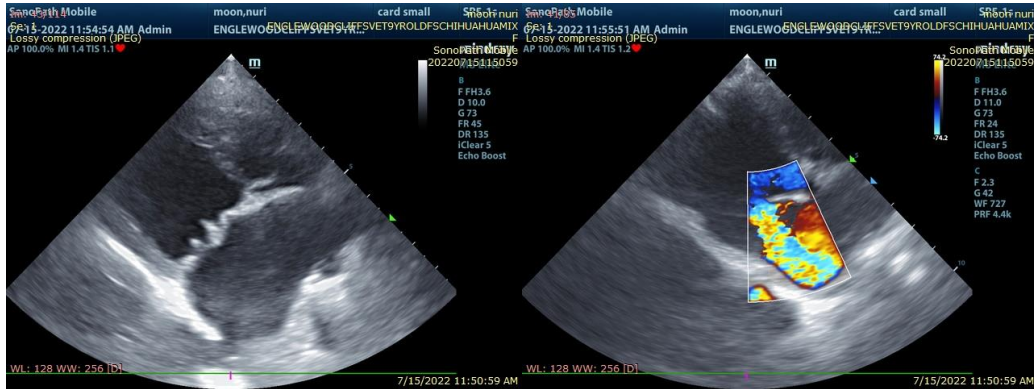
7/15/22

PERFORMED BY:

Kelly Vazquez

INTERPRETED BY

Keith Blass, DVM,
MS, DACVIM
(Cardiology)



The information and recommendations provided are based on the images presented by the referring veterinarian. No evaluation can be communicated regarding pathology that was not visible in the image/video clips provided.

PATIENT

Nuri Moon

Thank you for this referral. If the clinical or image interpretation does not parallel your findings or if I can be of any further assistance please contact me.

Keith Blass, DVM, MS, DACVIM (Cardiology)
KeithBlass@gmail.com
631-804-5754

SPECIES

Canine

BREED

Mixed

SEX

FS

AGE

9 y

WEIGHT

22.8 lb

HOSPITAL NAME

Englewood Cliffs VH

REFERRING VET

Dr. Attansi